

# Just Quiz

14-01-2015



**MediScan**

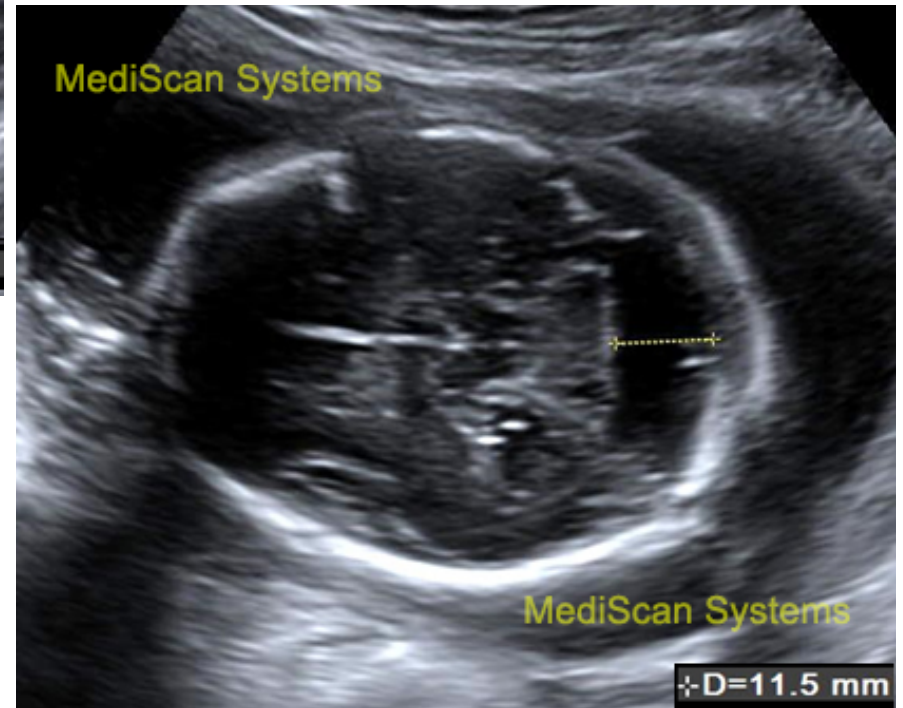
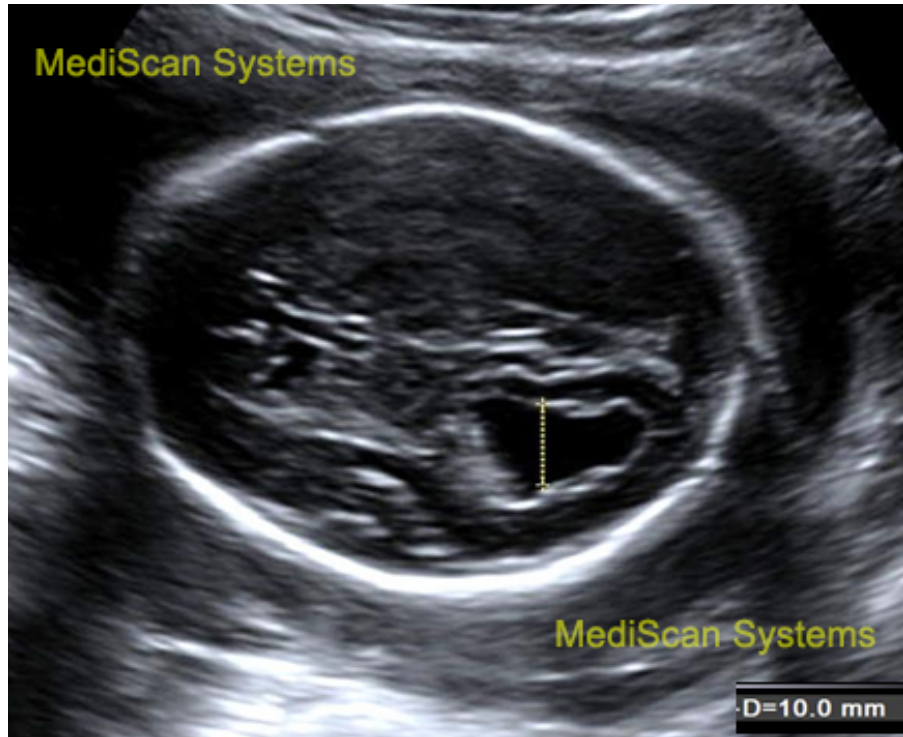
Ultrasound | Fetal Care | Genetics | Perinatal Pathology

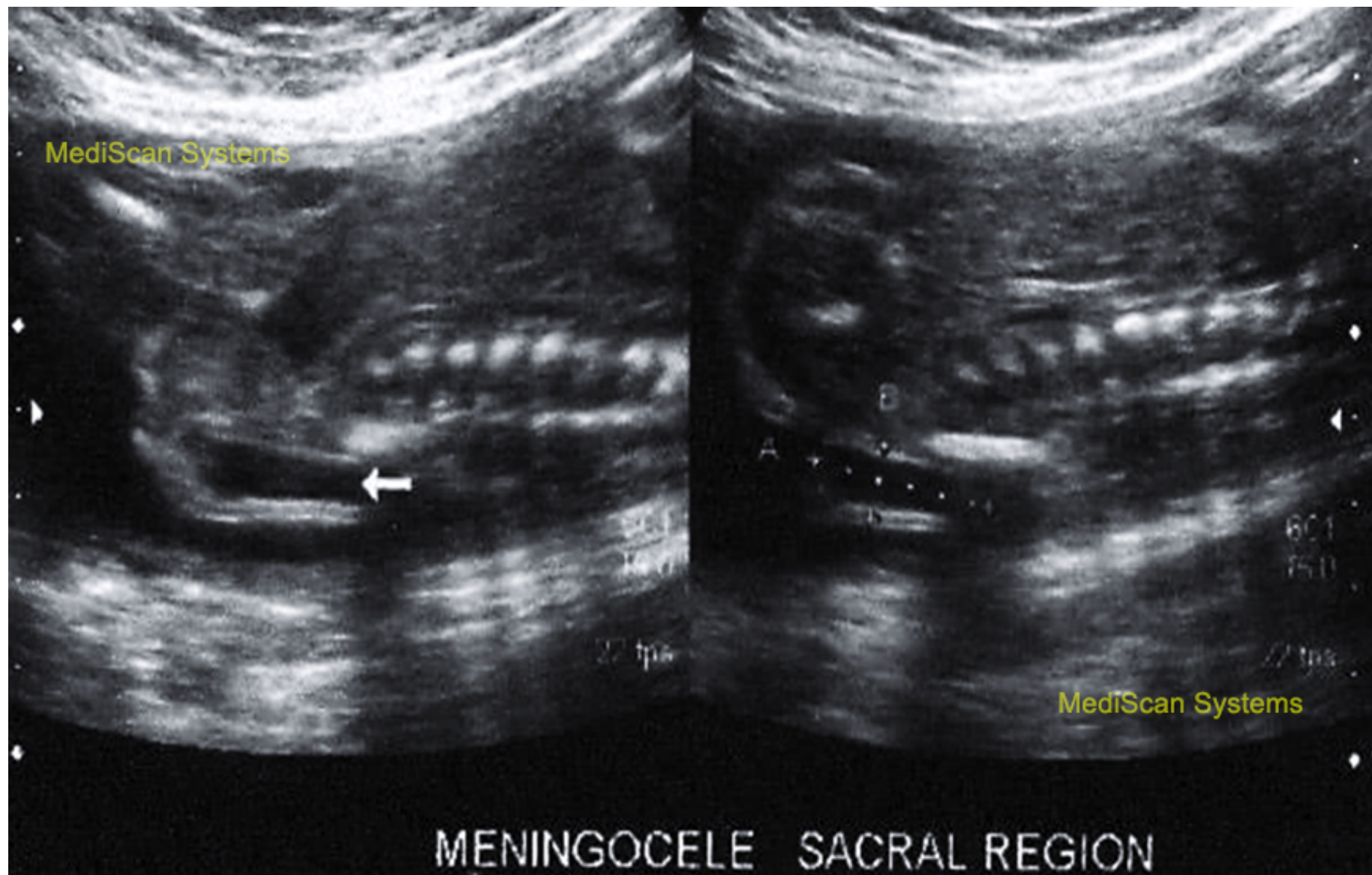
## Patient History

- Mrs.MS / 25 years
- Married 2 years
- B +ve
- 3<sup>o</sup> Consanguinity
- Primi
- Ref for II Opinion : ACM

Please comment on the images and the report

# 23 weeks gestation





# USG Report

*Colpocephaly. Prominent cisternamagna.*

*Hypo plastic cerebellum.*

Fetal skull normal in shape.

Fetal neck appear normal.

Heart is normal in situs.

Four chamber view is normal.

Note : All cardiac anomaly cannot be detected with FCV.

Suggested detailed cardiac study in high risk patients.

No intrathoracic mass lesions.

Stomach is visualised.

Both kidneys normal.

Urinary bladder is normal.

Umbilical cord insertion site appear normal.

*A cystic lesion at sacral region measuring 23.2 x 8.8 mm.*

*Suggestive meningocele.*

Dorso lumbar spine is normal. Genitals normal.

All four limbs visualised and appear normal.

## PLACENTA

Position : Posterior

Grade : I


AMNIOTIC FLUID : Adequate

Cervical length measures <sup>36.0</sup>mm. Internal OS closed.

## IMPRESSION :

- ❖ SINGLE LIVE INTRAUTERINE GESTATION OF 22 – 23 WEEKS MATURITY.
- ❖ FEATURES SUGGESTIVE OF ARNOLD CHIARI MALFORMATION.

Mail your answers to  
[mediscancme@gmail.com](mailto:mediscancme@gmail.com)



**MediScan**

Ultrasound | Fetal Care | Genetics | Perinatal Pathology